



**PRESENTING CLINICAL SIGNS**

**DATE** History: Previous echo showed very mild LAE. Asymptomatic.

**ECHOCARDIOGRAPHIC FINDINGS**

3/9/22 Multiple 2D, M-mode, and Doppler video loops and still images are submitted for review. This exam is compared to the one performed 9/20/21.

**PERFORMED BY**

Dr. Meredith Swart

**INTERPRETED BY**

Keith Blass, DVM,  
MS, DACVIM  
(Cardiology)

Left atrial size is normal. The mitral valve appears normal, though trace mitral regurgitation is present. Left ventricular wall thickness is normal. Left ventricular internal dimensions are normal. Left ventricular systolic function is normal. The aorta and aortic valve are normal. Right atrial and right ventricular dimensions are normal. The tricuspid valve is normal. The pulmonary artery and pulmonic valve appear normal. No shunting lesions are visualized. No pericardial effusion or cardiac masses are seen.

**PATIENT**

Stubbin Arguin

LA/Ao – 1.41 (prev. 1.51)  
IVSd – 4.5 mm (prev. 4.4 mm)  
LVPWd – 4.4 mm (prev. 4.3 mm)  
LVIDd – 14.5 mm (prev. 15.9 mm)  
LVIDs – 6.9 mm (prev. 7.7 mm)  
FS – 52.4% (prev. 51.6%)  
LVOT – 0.92 m/s (prev. 1.01 m/s)  
RVOT – 0.90 m/s

**SPECIES**

Feline

**ASSESSMENT/RECOMMENDATIONS**

This examination demonstrates resolution of Stubbin’s previously identified very mild left atrial dilation. Given this resolution, no evidence of primary cardiac disease is appreciated in today’s exam, therefore, Stubbin’s risk for the development of clinical signs of cardiac dysfunction appears to be low.

**BREED**

Sphinx

No therapy is recommended based on this exam.

**SEX**

A recheck echocardiogram is recommended if new physical exam and/or clinical abnormalities suggestive of cardiac dysfunction develop.

**MN**

**AGE**

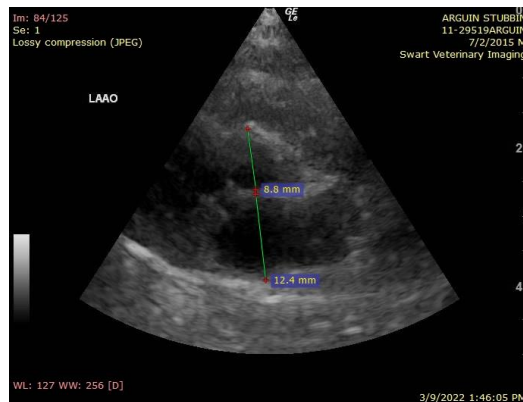
6 y

**WEIGHT**

7.6 lb

**HOSPITAL NAME**

Swart Veterinary  
Imaging



The information and recommendations provided are based on the images presented by the referring veterinarian. No evaluation can be communicated regarding pathology that was not visible in the image/video clips provided.

**REFERRING VET**

Dr. Swart

Thank you for this referral. If the clinical or image interpretation does not parallel your findings or



if I can be of any further assistance please contact me.

**DATE**

3/9/22

**Keith Blass, DVM, MS, DACVIM (Cardiology)**  
KeithBlass@gmail.com  
631-804-5754

**PERFORMED BY**

Dr. Meredith Swart

**INTERPRETED BY**

Keith Blass, DVM,  
MS, DACVIM  
(Cardiology)

**PATIENT**

Stubbin Arguin

**SPECIES**

Feline

**BREED**

Sphinx

**SEX**

MN

**AGE**

6 y

**WEIGHT**

7.6 lb

**HOSPITAL NAME**

Swart Veterinary  
Imaging

**REFERRING VET**

Dr. Swart